Case Report

AN ORBITAL MASS PRESENTING AS PRIMARY MONOPHASIC SYNOVIAL SARCOMA

Hassan Tariq, Syed Naeem Raza Hamdani, Shoaib Naiyar Hashmi, Saeed Afzal, Shahum Khan, Arooj Shahid

Armed Forces Institute of Pathology (National University of Medical Sciences), Rawalpindi, Pakistan

ABSTRACT

Introduction: Primary orbital monophasic synovial sarcoma is an extremely rare tumor with no case report in the literature.

Case presentation: A 37-year-old man presented with a twelve-year history of a progressively enlarging, painless mass in the left orbit which had resulted in lateral displacement of the eyeball. Examination showed the presence of a 6x4x3cm tumor on the medial side, associated with limited adduction of the left eye. A complete excision was performed and the eye was preserved. The patient is stable after surgery. Following the definitive histological report a thorough clinical and radiological search has been made for a primary lesion elsewhere in the head and neck, trunk, and limbs with negative results.

Conclusion: The diagnosis of monophasic primary orbital synovial sarcoma requires clinical, imaging and immunohistochemical investigation to exclude alternative primary sources. The treatment of choice is excision, which in most of cases is helpful for diagnosis. The prognosis is usually poor.

This case report can be cited as: Tariq H, Hamdani SNR, Hashmi SN, Afzal S, Khan S, Shahid A. An orbital mass presenting as primary monophonic synovial sarcoma. Pak J Pathol. 2016: 27(3): 173–177.

INTRODUCTION

Most orbital tumors are malignant in origin and carcinoma by nature. Synovial sarcoma is a malignant mesenchymal tumor, and accounts for 10% of all soft tissue sarcomas. It most often affects young adults and is usually found in periarticular sites of the extremities[1]. It may occur at other locations, including abdominal wall, head and neck, heart, mediastinum, and lung. Synovial sarcomas of the head and neck are rare, making up only 10% of all synovial sarcomas, and are commonly located at hypopharynx or parapharyngeal space.[2] We report a case of primary monophonic synovial sarcoma of the conjunctiva in a 37-year-old man with no significant medical history, who developed an enlarging orbital lesion of the left eye. Histological subtypes of the tumor is done on the basis of immunohistochemical markers, such as vimentin, desmin, actin, CD99, and epithelial membrane antigen. As most of the mesenchymal malignant tumors have a benign counterpart and some epithelial tumors have sarcomatoid differentiation (renal cell carcinoma, melanoma), specific histopathological diagnosis including evaluation of the grade of the lesion is very important. A definitive diagnosis requires detailed immunohistochemical staining [2,3] as well as clinical and imaging investigation to exclude alternative primary sources.

Correspondence: Dr Hassan Tariq, Pathologist, Department of Histopathology, Armed Forces Institute of Pathology (National University of Medical Sciences), Rawalpindi, Pakistan.

Email: **hassantariqamc@gmail.com**

Received: ***15 Aug 2016****; Revised:* ***26 Sep 2016****; Accepted:* ***17 Oct 2016***

CASE PRESENTATION

A 37-year-old man presented with a twelve-year history of a progressively enlarging, painless mass in the left orbit which had resulted in lateral displacement of the eyeball. Examination showed the presence of a 6x4x3cm tumor on the medial side, associated with limited adduction of the left eye. There was no significant past history, in particular, no apparent risk factors for acquired immunodeficiency or history of previous orbital irradiation. Ophthalmic examination showed no visual deficit. Computed tomograph (CT) scan showed no deep extension of the mass. General examination and CT staging of potential primary and metastatic tumor sites showed this to be a solitary lesion. A complete excision was

performed and the eye was preserved. The patient was stable after surgery. Following the definitive histological report a thorough clinical and radiological search has been made for a primary lesion elsewhere in the head and neck, trunk, and limbs with negative results.

PATHOLOGICAL FINDINGS

The specimen consisted of a lobulated mass of Soft grey white tissue measuring 6x4x3 cm with no normal surrounding tissue (Fig 1). Histologically it was composed of predominantly of areas of spindle cell growth with focal necrosis. Cells showed amphophilic cytoplasm and tapering vesicular nuclei with an indistinct nucleolus, nuclear hyperchromasia. The spindle cell component was also encasing some orbital glands (Fig 2). The cells showed up to with 0-5 mitotic figure per 10 hpf and were set in a predominantly myxoid but focally hyaline stroma. Within spindle cell areas there was a branching, thin-walled haemangiopericytomalike vascular pattern.

Immunohistochemical staining was positive for EMA, Bcl-2,TLE-1,CD99 while staining for CD-34 was negative . Ki 67 was 20-30 % Positive (Fig 2). The above findings were compatible with a monophonic spindle cell synovial sarcoma in the orbit.

Figure-1: Gross specimen (Well circumscribed orbital mass).

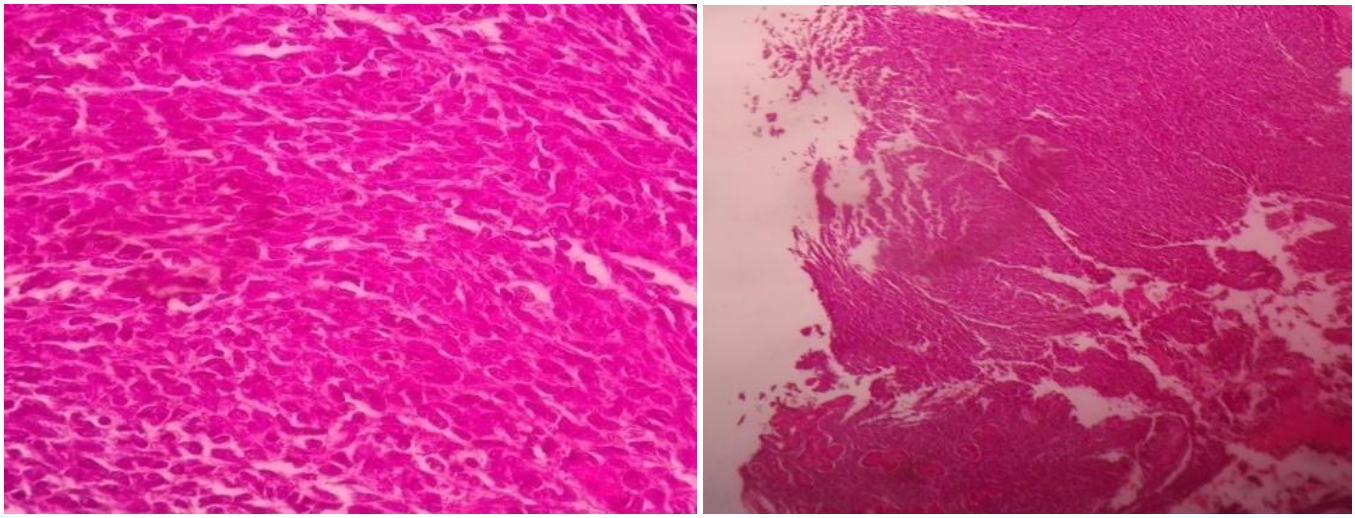

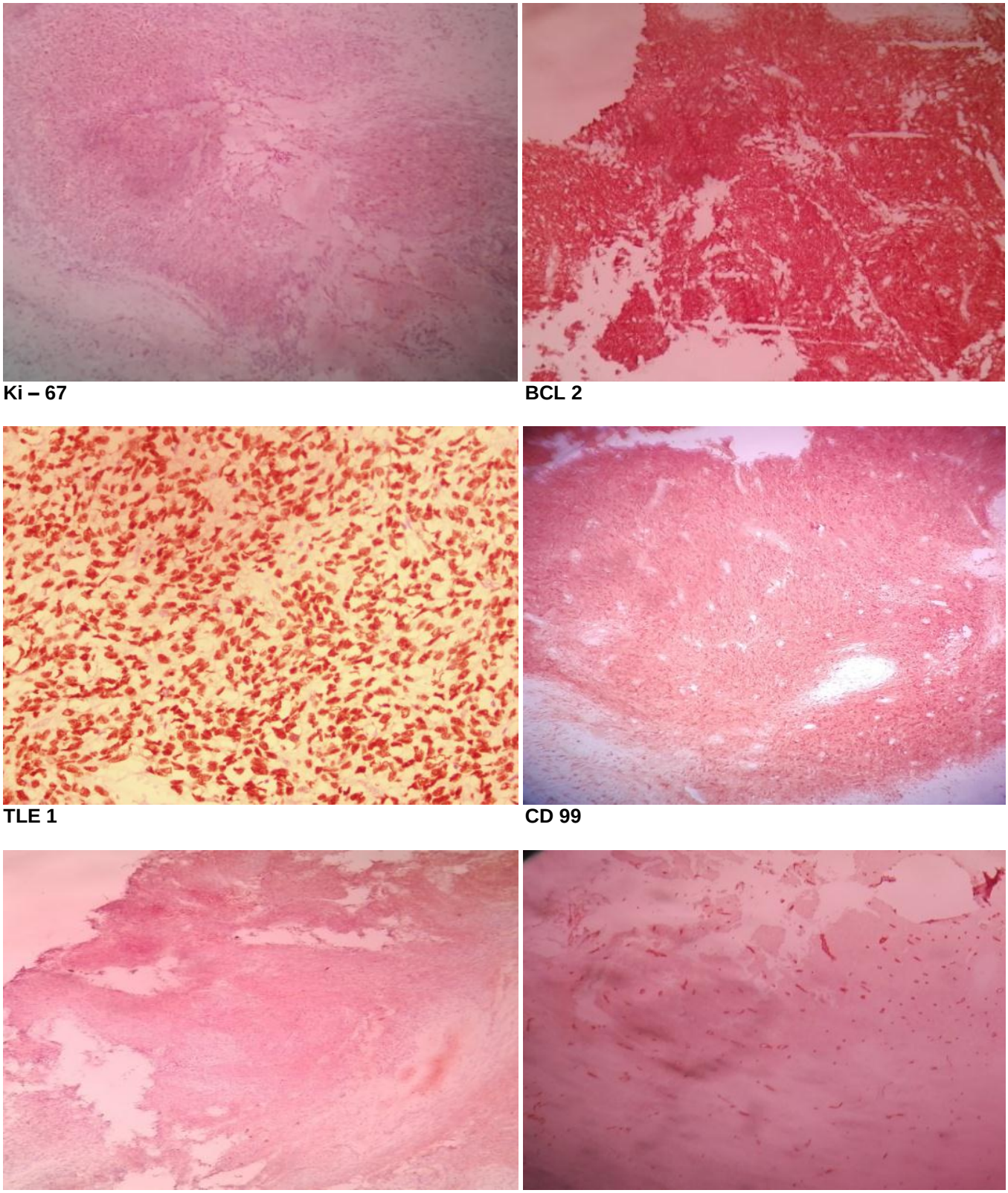

Ki – 67 **BCL 2**

TLE 1 **CD 99**

EMA **CD 34**

Figure-2:

DISCUSSION

Synovial sarcoma (SS) is a rare and well-established mesenchymal tumor, that makes up for approximately 10% of all soft tissue tumors [4,5]. SS usually occurs in adolescents and young adults, is most commonly found in the soft tissues of the extremities, but neck, lung, mediastinum, heart, and

abdominal wall sites have also been reported [5]. SS seems to be strongly related to cigarette smoking and is a highly aggressive tumor affecting males more often than females [6]. The term "synovial" sarcoma was assigned because of the synovial differentiation of the tumor that is believed to originate from multipotential mesenchymal cells.

The generally accepted histological subtypes of synovial sarcoma are biphasic, monophasic spindle cell or fibrous, monophasic epithelial and poorly differentiated subtypes [7]. The biphasic type can easily be diagnosed due to the presence of both epithelial and spindle cell components. The monophasic type is often difficult to diagnose, as it has a uniform spindle cell pattern leading to its confusion with other malignant spindle cell neoplasms, such as fibrosarcoma, hemangiopericytoma, leiomyosarcoma and spindle cell carcinoma or carcinosarcoma.

Immunohistochemistry plays a vital role in the diagnosis of SS, especially in monophasic type cases. Most synovial sarcomas show immunoreactivity for cytokeratins and epithelial membrane antigen (EMA). Furthermore, 30% of them are protein S-100 positive, 60–70% CD 99 positive and 75–100% Bcl-2 positive [8]. TLE is also positive in 80% biphasic, mono phasic and poorly differentiated tumours.

In difficult cases, the diagnosis of SS is augmented by the observation of the t(X;18) (p11.2;q11.2) chromosomal translocation characteristic of this neoplasm [5]. Furthermore, the development of fluorescence in situ hybridization (FISH) and reverse transcriptase–polymerase chain reaction (RT-PCR) techniques for the detection of either the t(X;18) or the SYT-SSX chimeric RNA transcript resulting from the t (X;18) of SS, in paraffin embedded tissue has offered a valuable diagnostic alternative, particularly when fresh tissue is not available for karyotypic analysis [5,6]. Despite its high sensitivity, molecular testing is not required if the diagnosis of synovial sarcoma is certain or probable on the basis of clinical, histological, and immunohistochemical evaluations [6,7].

Although primary orbital synovial sarcoma [8], and primary biphasic synovial sarcoma of the orbit [9] have been reported, we can identify no cases of a primary monophasic synovial sarcoma presenting as an orbital tumor. Other soft tissue sarcomas may present as a primary tumor of the conjunctiva, including malignant fibrous histiocytoma of the conjunctiva [10], and primary conjunctival rhabdomyosarcoma [11]. Benign leiomyoma of the caruncle [12] and leiomyosarcoma of the conjunctiva have been reported [13], as has conjunctival liposarcoma [14].

Complete surgical excision is the only curative option for adult soft tissue sarcomas. Adjuvant postoperative radiotherapy may reduce the risk of local relapse. Pediatric soft tissue sarcomas may respond to cytotoxic chemotherapy, but this is unusual in adult lesions. For soft tissue sarcoma of the conjunctiva, surgical adjuvant treatment with superficial radiotherapy (strontium-90) has been reported [11].

Although rare, primary synovial sarcoma should be considered in the differential diagnosis of orbital masses.

CONCLUSION

Primary orbital synovial sarcoma is a very rare neoplasm. Clinical and imaging investigation is necessary to exclude alternative primary sources. Definitive diagnosis requires detailed immunohistochemical staining (cytokeratins, vimentin, S100, CD20, CD99, Bcl-2, TLE and other markers). A balanced chromosomal translocation, t(X;18) (p11.2; q11.2), is found in the majority of synovial sarcomas resulting in a fusion protein, SYT-SSX, the role of which is so far unclear. Surgical excision with clear margins and possibly adjuvant

postoperative radiotherapy is the currently accepted treatment.

AUTHORS CONTRIBUTION

All authors work in Histopathology Department and contributed by gross and microscopic examination of the patient`s tissue.

Dr Hassan Tariq Wrote the manuscript.

REFERENCES

1. Mankin HJ, Hornicek FJ. Diagnosis, classification, and management of soft tissue sarcomas. Cancer Control. 2005; 12: 5 - 21.
2. Weiss SW, Goldblum JR. From malignant soft tissue tumors of uncertain type. In: Weiss SW, Goldblum JR, editor. Enzinger and Weiss's soft tissue tumors. 4. St. Louis: Mosby; 2001; 1483–1571.
3. Miettinen M, Limon J, Niezabitowski A, Lasota J. Calretinin and other mesothelioma markers in synovial sarcoma: analysis of antigenic similarities and differences with malignant mesothelioma. Am J Surg Pathol. 2001; 25: 610–17 .
4. Nagao K, Ito H, Yoshida H. Chromosomal translocation t(X,18) in human synovial sarcomas analyzed by FISH using paraffin-embedded tissue. Am J Pathol. 1996; 148: 601–9.
5. Hosono T, Hironaka M, Kobayashi A, Yamasawa H, Bando M, Ohno S, *et al*. Primary pulmonary synovial sarcoma confirmed by molecular detection of SYT-SSX1 fusion gene transcripts: a case report and review of the literature. Jpn J Clin Oncol. 2005; 35: 274–79.
6. Coindre JM, Pelmus M, Hostein I, Lussan C, Bui BN, Guillou L. Should molecular testing be required for diagnosing synovial sarcoma? Cancer. 2003 ;98: 2700–07.
7. Argani P, Zabowski MF, Klimstra DS, Rosai J, Ladanyi M. Detection of SYT-SSX chimeric RNA of synovial sarcoma in paraffin-embedded tissue and its application in problematic cases. Mod Pathol. 1998; 11: 65–71.
8. Ni C, Ma X. Histopathologic classification of 1921 orbital tumors. Yan Ke Xue Bao. 1995; 11: 101–4.
9. Ratnatunga N, Goodlad J, Sankarakumaran N, Seimon R, Nagendran S, Fletcher CD. Primary biphasic synovial sarcoma of the orbit. J Clin Pathol. 1992; 45: 265-67.
10. Allaire GS, Corriveau C, Teboul N. Malignant fibrous histiocytoma of the conjunctiva. Arch. Ophthalmol. 1999; 117: 685–7.
11. Sekundo W, Roggenkämper P, Fischer HP, Fleischhack G, Flühs D, Sauerwein W. Primary conjunctival rhabdomyosarcoma: 2.5 years' follow-up after combined chemotherapy and brachytherapy. Graefes Arch Clin Exp Ophthalmol. 1998; 236: 873 - 75.
12. Heegaard S, Prause JU. Leiomyoma of the caruncle. Acta Ophthalmol Scand. 1998; 76: 731–3.
13. White VA, Damji KF, Richards JS, Rootman J. Leiomyosarcoma of the conjunctiva. Ophthalmology. 1991; 98: 1560-64.
14. Miyashita K, Abe Y, Osamura Y. Case of conjunctival liposarcoma. Jpn J Ophthalmol. 1991; 35: 207–10.